



“The beauty of this operation is the control of the mid-face position that can be achieved. By maintaining the skin attachment to the SMAS superior and lateral to the nasolabial fold, effacement of the nasolabial fold occurs, resulting in improved contour.”

IN MY HANDS



Dr. Viennas

High SMAS
facial rejuvenation

Lambros K. Viennas, M.D.
Contributing Author

THE EVOLUTION of cosmetic facial surgery has resulted in a plethora of techniques that can be used to tailor a procedure for a patient's specific needs. Stigmata of facial aging that are addressed include rhytids, jowling, deep nasolabial folds, malar fat pad, lower eyelid fat pad herniation, eyelid ptosis, tear trough deformity, brow ptosis and platysma bands. Efforts to rejuvenate the central face must accomplish improvement of the nasolabial folds and re-establish the malar fat pad position. My preference for the past 10 years has been the high SMAS facelift championed by Dr. Fritz Barton, with modifications published by several authors.



Dr. Viennas

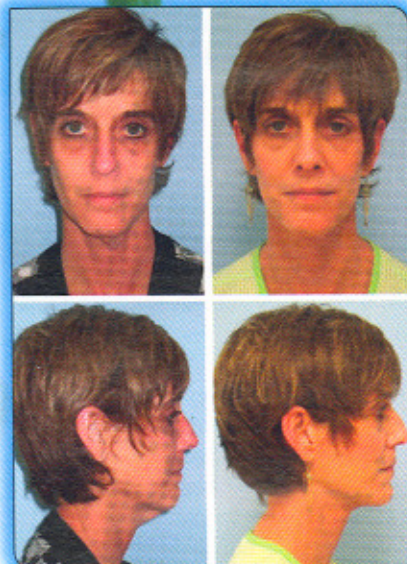
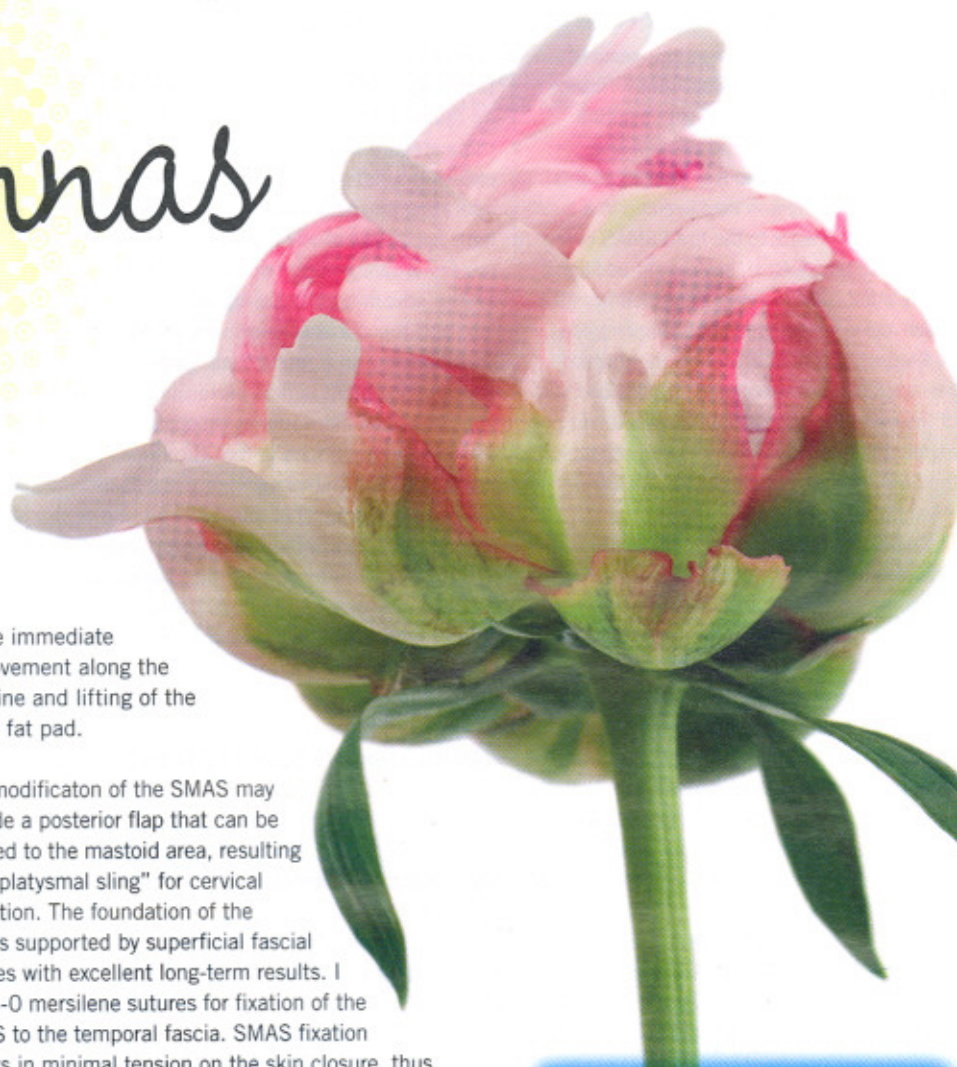
THE TECHNIQUE After raising a skin flap, the technique employs a SMAS dissection from the zygomatic arch to the malar fat pad medially, extending inferiorly from the preauricular sulcus to the platysma interface, while incrementally releasing retaining ligaments medially to allow mobilization of the mid-face. The beauty of this operation is the control of the mid-face position that can be achieved. By maintaining the skin attachment to the SMAS superior and lateral to the nasolabial fold, effacement of the nasolabial fold occurs, resulting in improved contour. In addition, arterial and venous perforators in this area are preserved for skin viability. I have also preserved perforator vessels in the neck, especially in thin female patients, to enhance blood supply to the skin. As the high SMAS flap is placed in the desired position, one will

notice immediate improvement along the jowl line and lifting of the malar fat pad.

One modification of the SMAS may include a posterior flap that can be sutured to the mastoid area, resulting in a "platysmal sling" for cervical definition. The foundation of the face is supported by superficial fascial sutures with excellent long-term results. I use 4-0 mersilene sutures for fixation of the SMAS to the temporal fascia. SMAS fixation results in minimal tension on the skin closure, thus reducing the risk of scar hypertrophy or widening and ischemia of the skin flap. Two drains are placed in the neck and a minimally compressive dressing is applied and removed the next day. I've noticed minimal post-operative swelling and ecchymosis over the past 10 years.

TAKE HEED The downside of this procedure is that a meticulous dissection is paramount to avoid nerve injury. Also, the skin flap dissection is thin and requires an atraumatic dissection (avoid pushing scissors). This operation takes time, but the results are great in the right patient. Some patients may require adjunctive measures including fillers or fat grafting. Most plastic surgeons employ various techniques to accomplish excellent results. Ultimately, selection of the procedure is dependent upon the patient's needs, and the surgeon's experience. ♦

Lambros K. Viennas, M.D., is a board-certified plastic surgeon in Virginia Beach, Va.



Photos credit: Lambros K. Viennas, M.D.

This patient underwent a high SMAS facelift only, shown before (left) and (right) one year post-op.